

Closed reduction in nasal fractures: a step-by-step description and brief literature review

Reducción cerrada en fracturas nasales: descripción paso a paso y breve revisión de la literatura

Escobar Riquelme, S.  Ballesteros Ibañez, N.  Macchiavello Macho, R.  Hernández Flores, J.P.  Gazitua Larrain, G. 

a. DDS, Universidad de Los Andes, Santiago, Chile.

b. DDS, Universidad Diego Portales, Santiago, Chile.

c. MD, Plastic Surgery Residency, Universidad Finis Terrae, Santiago, Chile.

d. DDS, OMF, Instituto Traumatológico Dr. Teodoro Gebauer Weisser, Santiago, Chile.

Recibido 2024-09-21

Revisado 2025-03-16

Aceptado 2025-04-07

Abstract

Introduction:

Nasal bone fractures represent one of the most prevalent facial injuries in adults, mainly attributable to the nose's prominent and exposed anatomical position.

These fractures constitute approximately 40% of all facial fractures and are frequently the result of high-impact events, such as motor vehicle collisions, sports-related trauma, and interpersonal violence.

Given the nose's integral role in facial aesthetics and respiratory function, managing nasal fractures is fundamental to ensure optimal outcomes in cosmetic appearance and functional restoration.

Objective:

This paper aims to present a step-by-step guide for performing a closed nasal reduction, using the clinical case of a patient with a nasal fracture as an example, along with a brief literature review on efficacy, aesthetic and functional considerations, and appropriate timing for intervention.

Case presentation:

A 47-year-old male patient presented to the emergency department with a nasal bone fracture sustained during an assault. Upon evaluation, the fracture was deemed suitable for management through closed reduction. A detailed step-by-step description of the closed reduction technique for nasal fractures, performed on the patient as an example, is provided. Post-procedure care included the use of internal and external splints, as well as a regimen of antibiotics and anti-inflammatory medications.

Conclusion:

Closed nasal reduction remains a widely used and effective procedure in the treatment of nasal bone fractures, particularly when performed early after injury.

The procedure is minimally invasive and can yield satisfactory aesthetic and functional outcomes. However, its success depends on factors such as the timing of the intervention and the surgeon's experience.

While closed reduction is effective for most simple fractures, more complex cases may require additional surgical interventions, such as nasal osteotomy, particularly if bone fusion has already occurred. The management of nasal fractures is an elementary skill that maxillofacial surgeons must have, given the prevalence of these injuries in emergency settings.

Escobar Riquelme, S., Ballesteros Ibañez, N., Macchiavello Macho, R., Hernández Flores, J.P., Gazitua Larrain, G. (2025) Closed reduction in nasal fractures: a step-by-step description and brief literature review, *Odontología Vital*, 2(43) 68-78. <https://doi.org/10.59334/ROV.v2i43.640>

Keywords:

Closed fracture reduction; Nasal bone; Nasal trauma; Bone fractures.

Resumen**Introducción:**

Las fracturas de los huesos nasales representan una de las lesiones faciales más prevalentes en adultos, atribuibles en gran medida a la posición anatómica prominente y expuesta de la nariz.

Estas fracturas constituyen aproximadamente el 40 % de todas las fracturas faciales y son con frecuencia el resultado de eventos de alto impacto, como accidentes automovilísticos, traumas que se relacionan con el deporte y violencia interpersonal. Debido al papel integral de la nariz, tanto en la estética facial como en la función respiratoria, el manejo de las fracturas nasales es fundamental para garantizar resultados óptimos en la apariencia cosmética y en la restauración funcional.

Objetivo:

El objetivo de este artículo es presentar una guía paso a paso para la realización de una reducción nasal cerrada, utilizando el caso clínico de un paciente con fractura nasal como ejemplo, junto con una breve revisión de la literatura sobre la eficacia, las consideraciones estéticas y funcionales y el momento adecuado para la intervención.

Presentación del caso: un paciente masculino de 47 años se presentó al servicio de urgencias con una fractura del hueso nasal sufrida durante una agresión.

Tras evaluarlo, se consideró que la fractura era adecuada para manejarla mediante reducción cerrada. Se proporciona una descripción detallada, paso a paso, de la técnica de reducción cerrada para fracturas nasales, que se realizó en el paciente como ejemplo. Los cuidados posoperatorios incluyeron el uso de férulas internas y externas, así como un régimen de antibióticos y medicamentos antiinflamatorios.

Conclusión:

La reducción nasal cerrada es un procedimiento ampliamente utilizado y efectivo en el tratamiento de fracturas de huesos nasales, en especial cuando se realiza poco después de la lesión.

El procedimiento es mínimamente invasivo y puede ofrecer resultados satisfactorios, tanto estéticos como funcionales. Sin embargo, su éxito depende de factores como el momento de la intervención y la experiencia del cirujano. Aunque la reducción cerrada es efectiva para la mayoría de las fracturas simples, los casos más complejos pueden requerir intervenciones quirúrgicas adicionales, como la osteotomía nasal, en particular si ya ha ocurrido la fusión ósea.

El manejo de las fracturas nasales es una habilidad fundamental que deben poseer los cirujanos maxilofaciales, debido a la prevalencia de estas lesiones en contextos de emergencia.

Palabras clave:

Reducción cerrada de fractura; hueso nasal; trauma nasal; fracturas óseas.

INTRODUCTION

Among the most frequent injuries to the facial bones in adults are nasal bone fractures. Their high incidence is due to the nose's prominence,

making it susceptible to impact and fractures, even with relatively low-energy blows (Jung et al., 2022). The epidemiology of these fractures varies depending on age, gender, and risk activities, with an incidence of approximately 40% of facial fractures (Nagaratna et al.,

2023; Trujillo & Lee, 2023). These fractures are frequently caused by automobile accidents, sports injuries, fights, among others (Plath et al., 2023).

Anatomy

The nose is a fundamental structure in the facial skeleton, playing an important role in facial aesthetics and respiratory physiology. From an anatomical perspective, the external nose is divided into three parts: the upper third consists of a bony structure, while the lower two-thirds comprise cartilage. The bony upper section, known as the vault, includes paired nasal bones that connect superiorly with the frontal bone at the nasion. Inferiorly, these nasal bones join the paired upper lateral cartilages at the rhinion. This combination of nasal bones and upper lateral cartilages shapes and supports the nasal dorsum. In the lower portion, the paired lower lateral (also called alar cartilages) shape the nasal tip and provide structure to the external nasal valve (Fig. 1) (Greenlund et al., 2023; Trujillo & Lee, 2023).

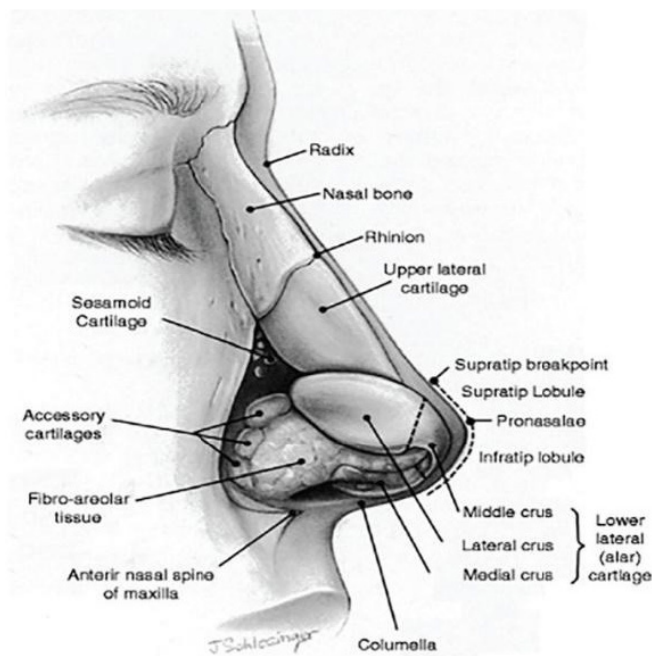


Figure 1. Anatomical depiction of the osteocartilaginous framework of the nose (Greenlund et al., 2023).

Fracture Classification

Currently, there is no universally standardized classification system for nasal bone fractures.

Nonetheless, Hwang et al. have suggested a system that divides these fractures into three primary categories: Type I: Simple without displacement; Type II: Simple with displacement; Type IIA: Unilateral; Type IIAs: Unilateral with septal fracture; Type IIB: Bilateral; Type IIBs: Bilateral with septal fracture; Type III: Comminuted (Fig. 2) (Hwang et al., 2006).

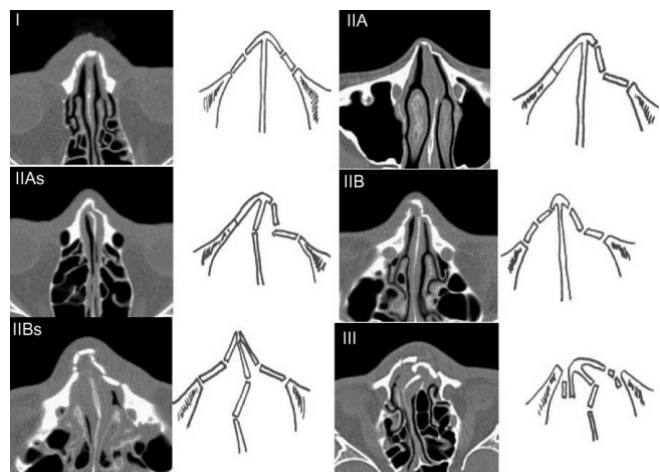


Figure 2. Classification of nasal fractures proposed by Hwang et al. (Hwang et al., 2006).

Closed Nasal Reduction

When treating nasal fractures, functionality and aesthetics are critical considerations. Closed reduction is a minimally invasive procedure designed to reposition the fractured bones, enhancing the appearance and minimizing septal deviation (Trujillo & Lee, 2023).

The main indications for closed reduction in a nasal fracture are primarily aesthetic deformities and changes in functionality. However, there are also several limitations and contraindications for this treatment, such as: excessive edema, which can lead to inadequate reduction; panfacial fractures, as the nasal fracture is often the last to be treated; naso-orbito-ethmoidal

fractures, as the nasal fracture is part of a more complex injury requiring special considerations; cerebrospinal fluid leak, which requires neurosurgical evaluation and management (Kademani et al., 2017).

The high prevalence of nasal fractures justifies the need for their management to also be the responsibility of the maxillofacial surgeon, an integral emergency team member responsible for the care of facial fractures.

To structure the research question guiding this work, the PICO model was used: (P) Adult patients with nasal bone fractures; (I) Closed reduction of the nasal fracture; (C) Other management options such as open reduction or conservative treatment; (O) Satisfactory aesthetic and functional results.

The research question was: "In adult patients with nasal bone fractures, is closed reduction effective in achieving satisfactory aesthetic and functional results, compared with other treatment options, such as open reduction or conservative treatment?" This paper aims to provide maxillofacial surgeons a comprehensive step-by-step guide to perform a closed nasal reduction by presenting a clinical case of a patient with a nasal fracture, accompanied by a brief literature review.

CASE REPORT

A 47-year-old male patient with no significant medical history presents to the emergency department following facial trauma due to an assault. Upon examination, the patient is conscious, lucid, and oriented to time and place. The evaluation reveals a nasal deformity with a right lateral deviation, left nasal compression, partial collapse of the left nostril, and reduced airflow through this side (Fig. 3).

Additionally, the patient reports difficulty breathing. Nasal speculum examination shows erythematous nasal mucosa, a nasal septum deviated to the right, and no septal hematoma. Waters' view radiograph (Fig. 4) and nasal bone radiographs (Fig. 5) are requested to confirm the nasal fracture.

Since the evaluation of the patient was made early, and the fracture involved just the nasal bones and not the septum, a closed reduction in an outpatient setting with local anesthesia was planned. Treatment was deferred for 7 days.

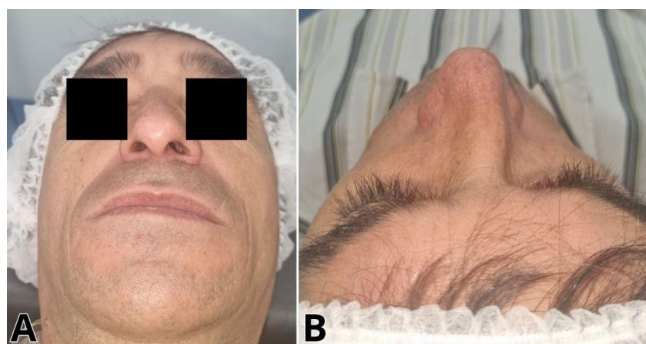

Figure 3. Preoperative appearance: (A) bottom view, (B) top view. A right deviation and a left nasal depression stand out.

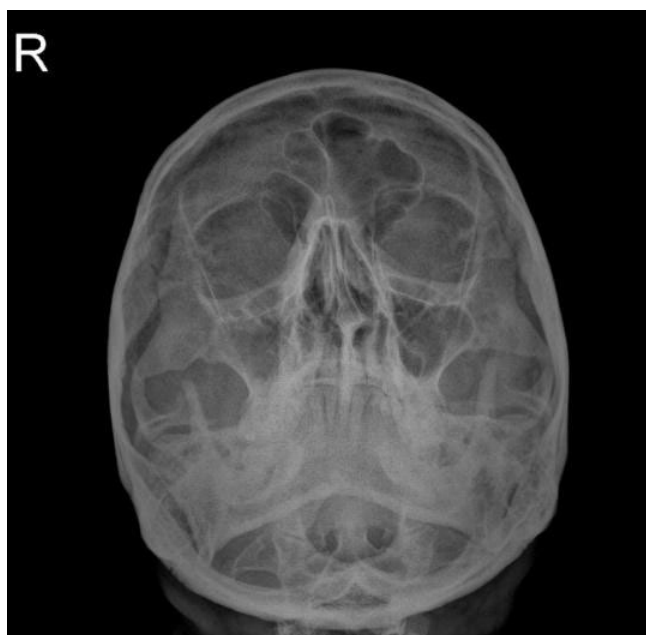

Figure 4 (A). Waters' radiograph shows the left HPN's collapse.

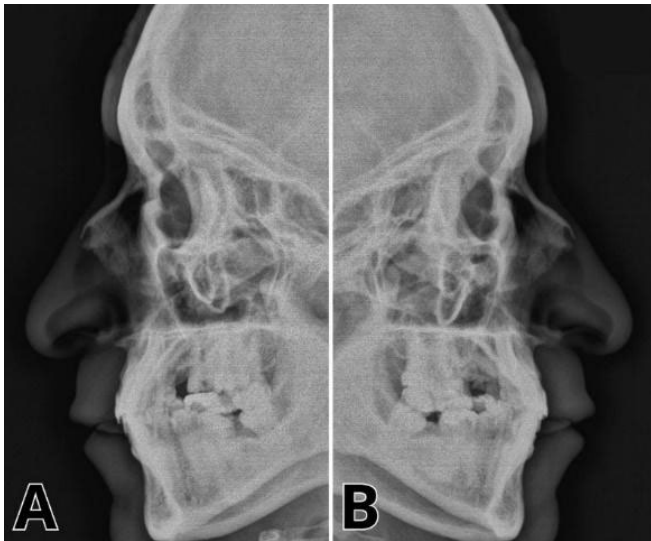

Figure 5 (A). Left HPN radiograph; (B) Right HPN radiograph.

Surgical Technique for Closed Nasal Reduction
Required Instruments

- Walsham Forceps
- Nasal Speculum
- Boies Elevator
- Asch Forceps
- Tweezer

These are shown in order, from left to right, in Figure 6.

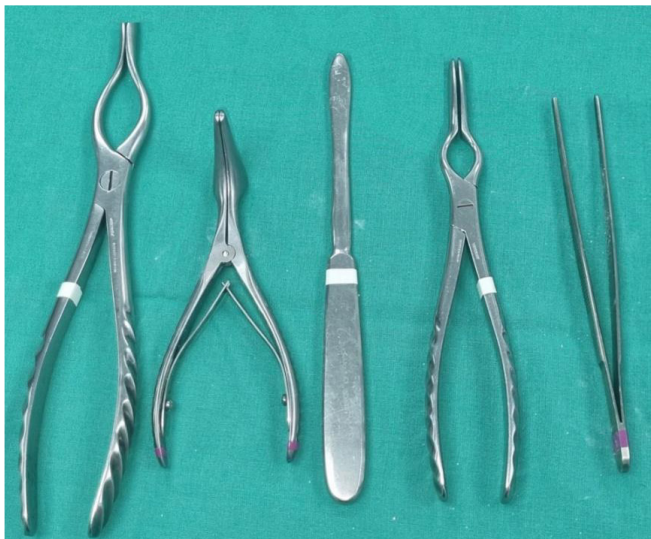

Figure 6: Instruments for the closed nasal reduction technique.

1. Local Anesthesia:

The procedure should be carried out using local anesthesia. Initially, infiltrative anesthesia is administered to the infraorbital and infratrochlear nerves using 2% Lidocaine combined with 1:100,000 Epinephrine (Fig. 7). Then, bilateral nasal packing with gauze soaked in 2% Lidocaine + 1:100,000 Epinephrine is performed, and 10 minutes are allowed to elapse, providing adequate mucosal anesthesia and vasoconstriction for the procedure (Fig. 8) (López-Cedrún, 2019).

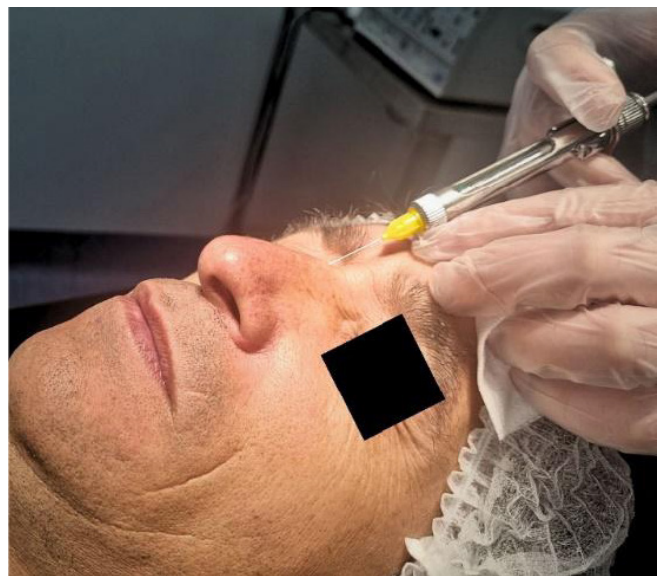

Figure 7. Infiltrative anesthesia of the infraorbital and infratrochlear nerves.

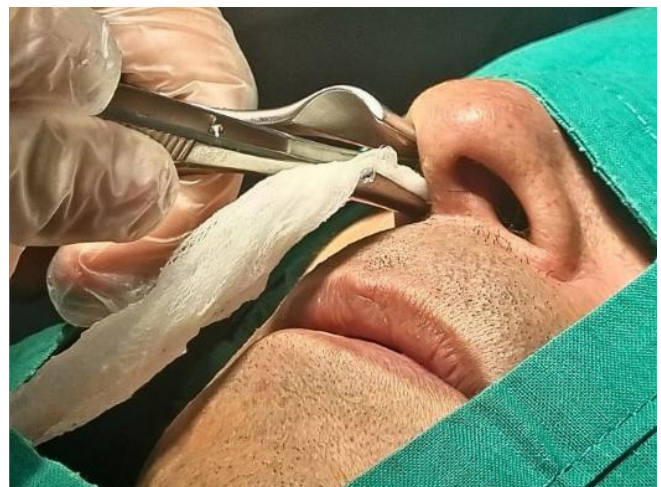

Figure 8. Bilateral nasal packing with gauze soaked in 2% lidocaine and vasoconstrictor to enhance anesthesia at the surgical site.

2. Straightening of the Nasal Pyramid

The deviated nasal pyramid is manually straightened by pressing the thumb on the deviated side, applying counterpressure on the contralateral hemiface to stabilize the head (López-Cedrún, 2019).

Measuring the instruments before insertion into the nasal cavities is essential, as the cribriform plate of the ethmoid bone, which connects the nasal cavity to the anterior cranial fossa, is situated in the upper region of the nasal cavity.

The measurement is taken from the base of the nose to the tip, subtracting 1 cm to obtain a safe measurement for instrument insertion, thereby reducing the risk of complications.

3. Reduction of Nasal Bone Depression:

Lateral Rectification with Boies Elevator:

The Boies elevator or a similar blunt-edged instrument of comparable size is inserted into the nasal cavity, positioned against the inner surface of the depressed nasal bone, and outward pressure is applied until lateral realignment is accomplished (Fig. 9) (López-Cedrún, 2019).

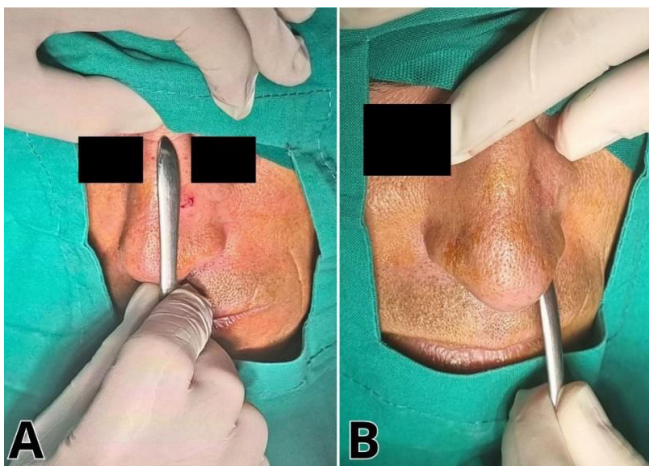


Figure 9 (A). Boies' elevator measurement from the tip of the nose to the root of the nose. **(B)** Application of force laterally using the Boies elevator.

Lateral Rectification with Asch Forceps:

The Asch forceps are introduced into the nostril on the affected side and closed, generating pressure on both the internal and external surfaces to rectify the lateral wall (Fig. 10).

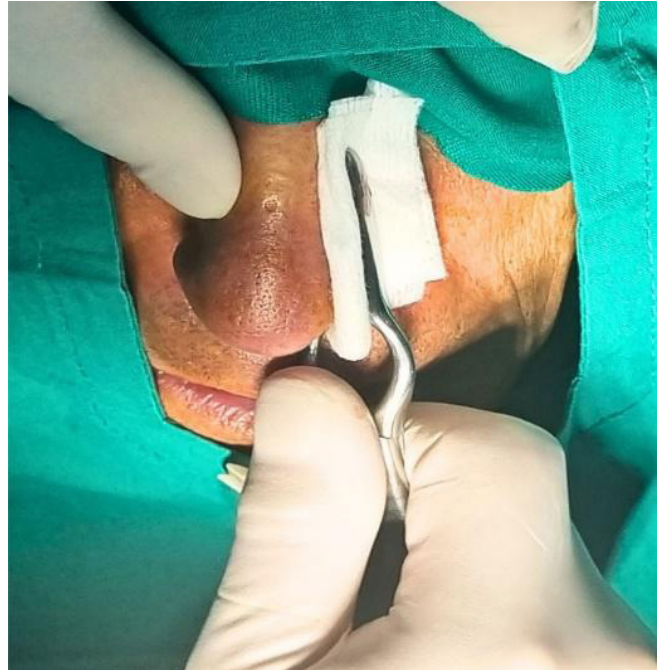


Figure 10: Asch forceps in operation on the left nostril to reduce the left nasal bone.

4. Evaluation and Treatment of the Nasal Septum:

The Walsham forceps are introduced, with each active part in each nostril, and closed to apply pressure on both internal walls of each nostril to rectify the septum's shape (Fig. 11).

After performing reduction maneuvers, it is essential to verify both nostrils' correct patency and rule out the presence of a septal hematoma.

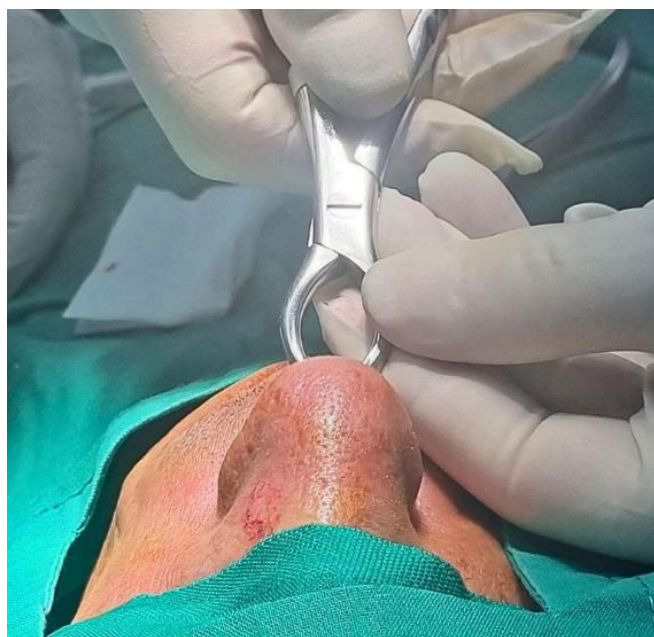

Figure 11. Walsham forceps in operation for nasal septum rectification.

5. Nasal Packing and External Splint:

Internal and external splinting is performed after completing the procedure and achieving fracture reduction (Fig. 12). Anterior packing with gauze is left in place to generate outward forces, maintaining the position of the cartilage and bones as an internal splint. Additionally, an external rigid splint, made of plaster bandage, is applied (Fig. 13), maintaining the reduction of the fragments and controlling the edema.

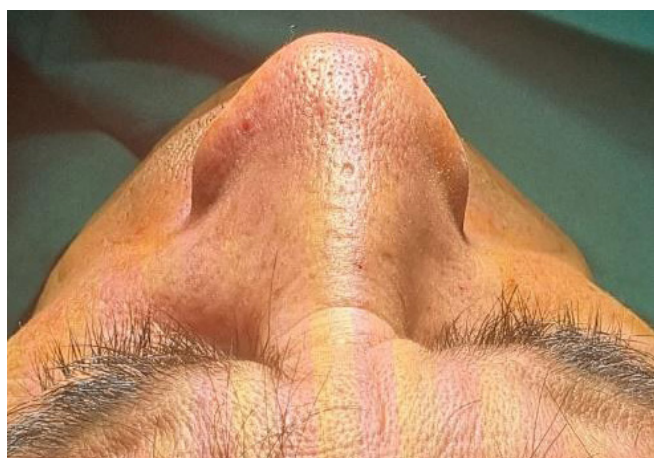


Figure 12. Post-reduction situation, highlighting the rectification of the nasal dorsum, from the nasion to the tip of the nose. The image is immediately post-reduction, so it is possible to see the inflammation and edema produced by the procedure.

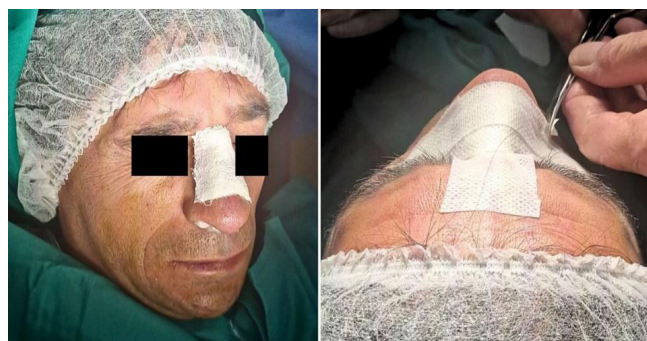

Figure 13. Fixation of internal and external splints using medical tape.

6. Post-operative Care

- Relative rest.
- Antibiotic therapy for 7 days.
- NSAIDs for 3 days.
- Maintain internal and external splints for 7 days.
- Sneeze with the mouth open.
- Avoid nose blowing.

DISCUSSION

This case highlights the importance of early evaluation in the management of nasal fractures, as it enabled the timely planning of a closed reduction, achieving satisfactory functional and aesthetic outcomes. Furthermore, this therapeutic approach contributed to reducing the associated costs for the patient and prevented the need for more invasive surgical intervention. These findings align with the evidence reported in recent studies, which support the effectiveness of closed reduction as a reliable therapeutic option for treating nasal fractures.

For instance, Rafiq et al. conducted a study comparing the aesthetic outcomes after surgery under local versus general anesthesia following

closed reduction of nasal bone fractures, emphasizing the common use of closed reduction for simple nasal fractures (Rafiq et al., 2023). According to a systematic review by James et al., the success rate of closed reduction of nasal fractures was 70% to 95% when performed early (James et al., 2020).

A study by Choi et al. showed that closed reduction in patients with nasal fractures can significantly minimize post-operative septal deviation in certain fracture types (Choi et al., 2022).

Conversely, Plath et al. found that individuals with nasal bone fractures generally experience more aesthetic improvements than functional benefits following closed reduction (Plath et al., 2023). These studies underscore closed reduction's ongoing relevance and effectiveness in managing nasal bone fractures.

Functional and Aesthetic Considerations

Complications arising from the closed reduction of a nasal fracture can be categorized into functional issues and deformities. Functionally, nasal fractures may result in septal deviation, impacting respiratory function even if the septum itself is not fractured. Choi et al. studied the impact of closed reduction in various nasal fracture patterns (without septal fractures) and its implications for septal deviation, finding that closed reduction significantly reduced septal deviation in all fracture types studied (unilateral, bilateral, and comminuted). However, comminuted fractures may result in persistent septal deviation despite the intervention (Choi et al., 2022). The aesthetic outcome depends on the level of deformity caused by the fracture, and evaluating it is always a challenge. Closed nasal reduction is the ideal treatment for cases with minor deformities or when aesthetics are

not a priority for the patient; otherwise, the ideal treatment is rhinoseptoplasty. Besmens et al. reported that the incidence of nasal deformities following reduction, which require rhinoplasty or rhinoseptoplasty, falls between 14% and 15% (Besmens et al., 2023).

Regarding patient perception, Park et al. examined patients' quality of life post-closed reduction for nasal bone fractures, shedding light on the overall satisfaction and outcomes following the procedure (Park et al., 2023). Furthermore, a more recent study conducted by Sánchez-Álvarez et al. evaluated aesthetic satisfaction using a subjective scale, and the median total score increased from 32 to 72 points after closed reduction. Items related to size, shape, and overall aesthetic appearance received the highest scores (Sánchez-Álvarez et al., 2023). These studies provide updated insights into the functional and aesthetic outcomes of closed reduction in nasal fractures, highlighting the importance of patient satisfaction and longterm results.

Time of intervention

Opinions vary regarding the appropriate timing for intervention in isolated nasal bone fractures and their impact on outcomes. Many experts recommend early reduction for pediatric patients, typically within 7 days due to their faster healing rates, and within 10 days post-injury for adults (Wang et al., 2019).

Trujillo et al. suggest an immediate closed reduction is feasible if the patient receives care within 3 to 6 hours of the injury, before significant swelling occurs. Beyond this period, it is generally advisable to postpone the procedure until the swelling subsides, which may take up to 14 days in adults.

However, authors like Yoon and Han have reported successful outcomes even when treatment was administered up to 41 days after the injury (Yoon & Han, 2016).

Additionally, Koca et al. advised waiting 3–5 days for the swelling to subside following the initial diagnosis of a nasal fracture before deciding on the most suitable treatment approach, providing a window for evaluation and planning in the early phase of the injury (Firat Koca et al., 2022).

Many experts recommend early reduction for pediatric patients, typically within 7 days due to their faster healing rates, and within 10 days post-injury for adults (Wang et al., 2019). Trujillo et al. suggest an immediate closed reduction is feasible if the patient receives care within 3 to 6 hours of the injury, before significant swelling occurs.

Beyond this period, it is generally advisable to postpone the procedure until the swelling subsides, which may take up to 14 days in adults.

However, authors like Yoon and Han have reported successful outcomes even when treatment was administered up to 41 days after the injury (Yoon & Han, 2016).

This approach underscores the importance of monitoring the patient's condition and edema resolution before proceeding with intervention to ensure optimal outcomes.

Kang et al. emphasized the significance of early intervention for pediatric nasal fractures, noting that children's faster bone healing process necessitates an earlier reduction compared to adults to ensure optimal surgical outcomes (Kang et al., 2021).

In conclusion, when swelling is significant enough to hinder the intraoperative assessment of the underlying nasal bones, it is permissible to postpone closed nasal reduction for 7 to 10 days, or potentially longer, to allow the skin swelling to subside, with the preference being that this occurs prior to bony fusion.

Should bony fusion have already taken place, closed nasal reduction may necessitate a concurrent nasal osteotomy to reposition the displaced bone segment (Wang et al., 2019).

CONCLUSION

Closed nasal reduction in nasal fractures that meet the aforementioned criteria can be safely performed in the acute setting by Maxillofacial surgeons, as it helps minimize secondary rhinoseptoplasty, saving patients time and money with acceptable long-term results.

However, it is not always indicated that if bone fusion has already occurred, closed nasal reduction may also require concurrent nasal osteotomy to mobilize the displaced bone segment, highlighting the importance of properly referring such cases to otolaryngology.

Finally, as one of the most prevalent fractures seen in emergency settings, its diagnosis and management should be known to all Maxillofacial surgeons.

AUTHOR CONTRIBUTION:

The authors have contributed to the conception, planning, execution and approval of the final version of this article.

Conflict of interest:

The authors declare that they have no conflicts of interest.

Funding:

Conceptualización y diseño: SE, JH
 Revisión de literatura: SE, NI, RM
 Metodología y validación: SE, JH
 Análisis formal: SE, NI
 Investigación y recopilación de datos: SE, NI, RM
 Recursos: GG, RM, SE
 Análisis e interpretación de datos: SE, NI
 Redacción-preparación borrador original: SE, NI
 Redacción-revisión y edición: SE, NI, RM, JH, GG
 Supervisión: JH, GG
 Administración de proyecto: SE, JH, GG

REFERENCES

- Besmens, I. S.; Shahrदार, C.; Fontein, D. B. Y.; Knipper, S.; Giovanoli, P. y Lindenblatt, N. (2023). Efficacy of closed reduction of nasal fractures—a retrospective analysis with focus on factors affecting functional and aesthetic outcomes. *Journal of Plastic, Reconstructive & Aesthetic Surgery: JPRAS*, 77, 371–378. <https://doi.org/10.1016/j.bjps.2022.11.010>
- Choi, J. H.; Oh, H. M.; Hwang, J. H.; Kim, K. S. y Lee, S. Y. (2022). Do closed reduction and fracture patterns of the nasal bone affect nasal septum deviation? *Archives of Craniofacial Surgery*, 23(3), 119–124. <https://doi.org/10.7181/acfs.2022.00661>
- Greenlund, L. K.; Tan, S. R. y Dresner, H. S. (2023). Nasal sesamoid cartilages: Fact or fiction? An anatomical study of the lateral nasal ala. *The Annals of Otology, Rhinology, and Laryngology*, 132(11), 1438–1442. <https://doi.org/10.1177/00034894231165134>
- Hwang, K.; You, S. H.; Kim, S. G. y Lee, S. I. (2006). Analysis of nasal bone fractures: a six-year study of 503 patients. *The Journal of Craniofacial Surgery*, 17(2), 261–264. <https://doi.org/10.1097/0001665-200603000-00010>
- James, J. G.; Izam, A. S.; Nabil, S.; Rahman, N. A. y Ramli, R. (2020). Closed and Open Reduction of Nasal Fractures. *The Journal of Craniofacial Surgery*, 31(1), e22–e26. <https://doi.org/10.1097/SCS.00000000000005812>
- Jung, S.; Yoon, S. y Kim, Y. (2022). Epidemiology and patterns of nasal bone fracture in elderly patients in comparison to other age groups: An 8-year single-center retrospective analysis. *Archives of Craniofacial Surgery*, 23(5), 205–210. <https://doi.org/10.7181/acfs.2022.00794>
- Kademani, D. y Tiwana, P. S. (2017). *Atlas de cirugía oral & maxilofacial: Vol. I. Amolca*.
- Kang, W. K.; Han, D. G.; Kim, S.-E.; Lee, Y. J. y Shim, J. S. (2021). Comparison of post-operative outcomes between early and delayed surgery for pediatric nasal fractures. *Archives of Craniofacial Surgery*, 22(2), 93–98. <https://doi.org/10.7181/acfs.2021.00122>
- Koca, C.; Celik, T.; Aydin, S.; Kelles, M. y Yasar, S. (2022). Effects of the COVID-19 Pandemic on Pediatric Nasal Fractures. *Ear, Nose, & Throat Journal*, 101(4), 239–244. <https://doi.org/10.1177/01455613211051309>

López-Cedrún, J. (2019). *Cirugía oral y maxilofacial: Atlas de procedimientos y técnicas quirúrgicas*. Editorial Médica Panamericana.

Nagaratna, H. K. y Ramashesh, R. (2023). Etiology and patterns of fracture in maxillofacial trauma- a prospective study. *International Journal Of Scientific Research*, 36, 36-39. <https://doi.org/10.36106/ijsr/0107322>

Park, G. W.; Park, C. H.; Kwon, J. H. y Park, T. J. (2023). A case of nasal bone fracture with septal fracture reduction via closed reduction of nasal bone fracture and endoscopic septoplasty. *Journal of Cosmetic Medicine*, 7(2), 84-87. <https://doi.org/10.25056/JCM.2023.7.2.84>

Plath, M.; Cavaliere, C.; Seide, S.; Hohenberger, R.; Plinkert, P. K.; Baumann, I. y Zaoui, K. (2023). Does a closed reduction improve aesthetic and functional outcome after nasal fracture? *European Archives of Oto-Rhino-Laryngology: Official Journal of the European Federation of Oto-Rhino-Laryngological Societies (EUFOS): Affiliated with the German Society for Oto-Rhino-Laryngology - Head and Neck Surgery*, 280(5), 2299-2308. <https://doi.org/10.1007/s00405-022-07754-4>

Rafiq, S.; Rafiq, F.; Ali, N.; Rehman, A.; Saleem, M. y Hussain, B. (2023). Comparison of post-operative aesthetic outcome between local and general anesthesia after close reduction for nasal bone fracture. *Annals of Punjab Medical College*, 17, 344-347. <https://doi.org/10.29054/APMC/2023.1504>

Sánchez-Álvarez, D. C.; Ramírez-Rivero, C. E.; Ruiz-González, C. E.; Navas, A. G.; Villarreal, D. C.; Sánchez-Álvarez, D. C.; Ramírez-Rivero, C. E.; Ruiz-González, C. E.; Navas, A. G. y Villarreal, D. C. (2023). Satisfacción estética y funcional tras reducción cerrada de fracturas nasales: Implementación de la escala NOSE. *Cirugía Plástica Ibero-Latinoamericana*, 49(3), 217-224. https://scielo.isciii.es/scielo.php?script=sci_arttext&pid=S0376-78922023000300003

Trujillo, O. y Lee, C. (2023). Nasal Fractures: Acute, Subacute, and Delayed Management. *Otolaryngologic Clinics of North America*, 56(6), 1089-1099. <https://doi.org/10.1016/j.otc.2023.05.004>

Wang, W.; Lee, T.; Kohlert, S.; Kadakia, S. y Ducic, Y. (2019). Nasal Fractures: The Role of Primary Reduction and Secondary Revision. *Facial Plastic Surgery: FPS*, 35(6), 590-601. <https://doi.org/10.1055/s-0039-1700801>

Yoon, H. Y. y Han, D. G. (2016). Delayed reduction of nasal bone fractures. *Archives of Craniofacial Surgery*, 17(2), 51-55. <https://doi.org/10.7181/acfs.2016.17.2.51>



Derechos de autor ©2025 Escobar Riquelme, S., Ballesteros Ibañez, N., Macchiavello Macho, R., Hernández Flores, J.P., Gazitua Larraín, G.

Esta obra esta bajo una Licencia Creative Commons Atribución 4.0 Internacional (CC BY 4.0)